

# Acute Ischemic Stroke in a Young Woman With No Known Risk Factors

Noureldin Abdelhamid, MD; Salman Farooq, MD; Amrou Sarraj, MD

## ABSTRACT

**Introduction:** We aim to highlight a potentially morbid consequence of foam-sclerotherapy for the treatment of varicose veins.

**Case Report:** We report a case of a 41-year-old woman with no significant medical history who presented to the emergency department with sudden onset of focal neurologic deficits. She had undergone varicose vein treatment with foam sclerotherapy 2 days prior. Magnetic resonance imaging of the brain showed acute cerebellar infarct. Computed tomography angiography was unremarkable. Transesophageal echocardiography showed the presence of a very small patent foramen ovale.

**Discussion:** Transient neurologic symptoms reported in patients undergoing venous foam sclerotherapy might have been transient ischemic attacks or acute ischemic strokes. The risk of these neurologic complications should be explained to all patients undergoing foam sclerotherapy so they can make an informed decision of screening echocardiography prior to the procedure.

**Conclusion:** Onset of neurologic symptoms can be immediate or delayed in patients undergoing venous foam sclerotherapy. Early recognition of neurologic deficits resulting from paradoxical gas embolism and its treatment with hyperbaric oxygen can prevent permanent disability.

## BACKGROUND

Foam sclerotherapy has gained wide recognition for the treatment of varicose veins mainly because of its immediate efficacy and low complication rates. A few major trials demonstrated minor side effects from the procedure in only a few patients, and the most commonly reported side effects occurred at the site of injection

• • •

**Author Affiliations:** Department of Neurology, University of Texas Health Science Center at Houston, Houston, Tex (Abdelhamid, Sarraj); Department of Neurology, Medical College of Wisconsin, Milwaukee, Wis (Farooq).

**Corresponding Author:** Salman Farooq, MD, Resident Physician, Neurology, Medical College of Wisconsin, 9200 W Wisconsin Ave, Milwaukee, WI; phone 313.204.2932; email salmanfarooq196@gmail.com, sfarooq@mcw.edu.

including hyperpigmentation and pain.<sup>1</sup> Neurologic complications, including transient visual disturbances and headaches, have been reported in a few cases.<sup>1-3</sup> In addition, a few cases of acute ischemic stroke following foam sclerotherapy are reported in the literature, which raised a few morbidity/mortality concerns about the procedure but not sufficient enough to introduce the practice of routine screening echocardiogram in patients undergoing this procedure.<sup>2-5</sup>

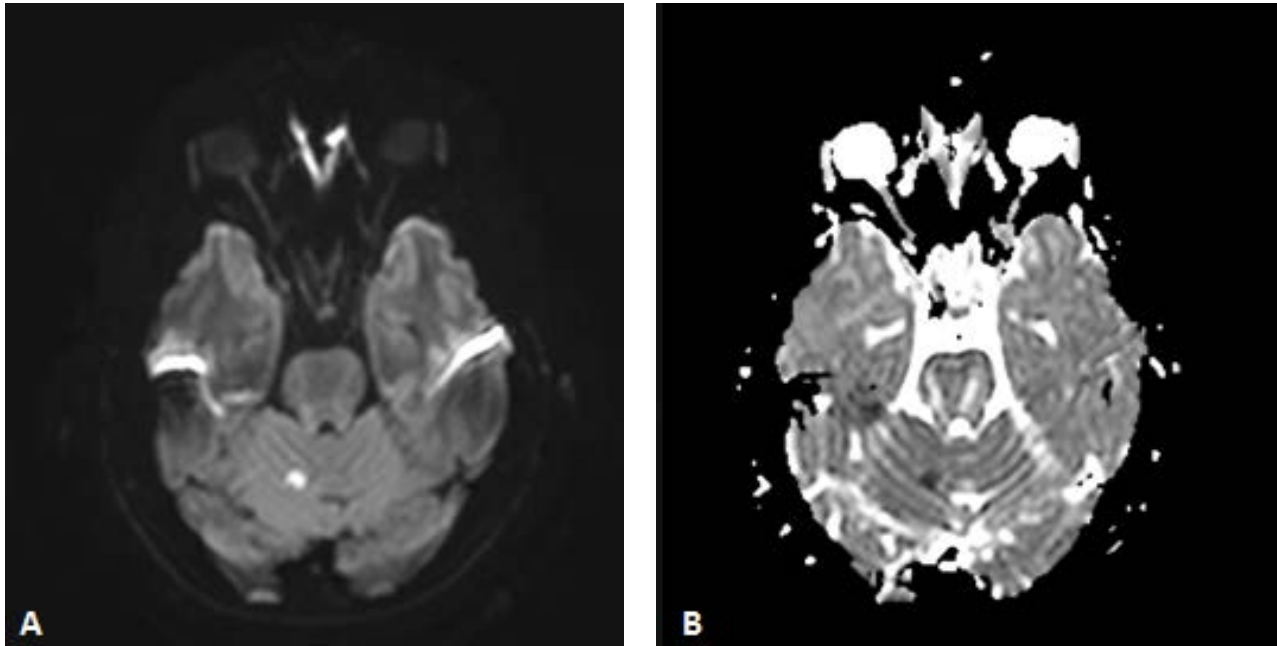
## CASE REPORT

A 41-year-old right-handed woman with no significant past medical history presented to the emergency department (ED) with sudden onset of slurred speech with right arm weakness and incoordination. She had undergone varicose vein treatment

with foam sclerotherapy 2 days prior. She was working at home when she developed a pain in her right lower extremity that felt like a charley horse at the site of the vein treatment. She stood up to stretch her leg, when she suddenly developed aphasia with intact thought process and cognition but inability to form words followed by slurred speech. She then became very dizzy and nauseous and noticed weakness and incoordination greatest in her right upper extremity and had difficulty dialing 911. She was transported to the ED, and the symptoms had resolved by the time she arrived about 45 minutes later.

During the episode, she reported some blurry vision and her husband also reported very mild right-sided facial droop that had since resolved. She denied any headaches, neck pain, vomiting, numbness, tingling or residual weakness. Head computed tomography (CT) was negative for acute ischemia or hemorrhage, and initial labs and vital signs were within normal limits. General

**Figure.** Magnetic Resonance Imaging of the Brain



**A.** Diffusion-weighted image. **B.** Apparent Diffusion Coefficient image showing small focus of acute infarction in superior right cerebellum.

physical and neurological exam was normal. National Institutes of Health Stroke Scale was 0. Magnetic resonance imaging (MRI) of the brain showed a small focus of acute infarct in superior right cerebellum (Figure). The patient was not a candidate for reperfusion therapy. She was started on aspirin 325 mg and admitted for transient ischemic attack/stroke work-up. Duplex ultrasound of lower extremities was negative for deep vein thrombosis (DVT). CT angiography was negative for extracranial or intracranial atherosclerosis. Transthoracic echocardiography was unremarkable (no valvular abnormalities; normal chamber size, EF: 60-65%, no intra-cardiac shunt). Transesophageal echocardiography showed the presence of a very small patent foramen ovale. Magnetic resonance venography for pelvis was negative for DVT or residual foam/gas bubbles.

## DISCUSSION

Foam sclerotherapy of varicose veins has gained popularity over other methods of sclerotherapy mainly because of its high success rate, low rate of complications, and almost negligible morbidity and mortality issues. In this procedure, a mixture of gas and liquid sclerosing solution is injected in the veins that produce endothelial damage and thrombus formation, resulting in vein occlusion.<sup>1,5</sup> Complications commonly reported from this procedure include local pigmentation, skin necrosis, and malaise. Neurologic complications also have been uncommonly reported including headache, transient confusional status, and transient visual disturbance.<sup>1-3</sup> Acute ischemic stroke following foam sclerotherapy is reported

in a few case reports, and the most common risk factor seen in these patients was the presence of an intracardiac or intrapulmonary shunt resulting in paradoxical embolism.<sup>2-5</sup> Paradoxical gas emboli introduced by foam sclerotherapy block blood supply to small arteries supplying the brain with an immediate or delayed onset of stroke, as seen in our patient, after foam sclerotherapy. The proposed mechanisms of cerebral ischemia caused by gas embolism include local obstruction to blood flow, vasospasm, endothelial damage caused by the induction of platelets or direct activation of thrombin.<sup>3,5</sup>

Unfortunately, no screening criteria have been established for the presence of intracardiac or extracardiac shunts when selecting patients for this procedure. The few reported cases of acute ischemic stroke following this procedure were all immediate in onset, but the onset of symptoms can be delayed as the entrapped air bubbles find a way into systemic circulation by increased activity or stretching of calf muscles, as seen in our case. And we believe that the previously reported cases of transient visual disturbance or confusion states following this procedure were possibly transient ischemic attacks resulting from paradoxical embolism of small gas bubbles.<sup>1</sup>

If physicians are able to recognize the etiology by a good procedural history, permanent neurologic deficits from air embolism induced ischemia can be prevented by administration of hyperbaric oxygen, as reported by Adatia et al<sup>3</sup> and Leslie-Mazwi et al.<sup>5</sup> Hyperoxia induced by hyperbaric oxygen decreases the size of air bubbles by causing oxygen to diffuse into bubble and nitrogen to

diffuse out of the bubble and also reduces adherence of platelets to damaged endothelium.<sup>3,5</sup>

## CONCLUSION

The risk of neurologic complications (including transient ischemic attack and acute ischemic stroke) should be explained to all patients undergoing venous foam sclerotherapy so they can make an informed decision of screening echocardiography prior to the procedure.

Onset of neurologic symptoms can be immediate or delayed in patients undergoing venous foam sclerotherapy. Early recognition of neurologic deficits resulting from paradoxical gas embolism and its treatment with hyperbaric oxygen can prevent permanent disability. All such patients should have a work-up to rule out the presence of gas bubbles in circulation that could pose a continued risk for further ischemic events.

**Funding/Support:** None declared.

**Financial disclosures:** None declared.

---

## REFERENCES

1. Frullini A, Cavezzi A. Sclerosing foam in the treatment of varicose veins and telangiectases: history and analysis of safety and complications. *Dermatol Surg.* 2002;28(1):11-15.
2. Forlee MV, Grouden M, Moore DJ, Shanik G. Stroke after varicose vein foam injection sclerotherapy. *J Vasc Surg.* 2006;43(1):162-164.
3. Adatia S, Nambiar V, Kapadia R. Acute ischemic stroke caused by paradoxical air embolism following injection sclerotherapy for varicose veins. *Neurol India.* 2013;61(4):431-433. doi: 10.4103/0028-3886.117596.4.
4. Hanisch F, Muller T, Krivokuca M, Winterholler M. Stroke following variceal sclerotherapy. *Eur J Med Res.* 2004;9:282-284.
5. Leslie-Mazwi TM, LL Avery, Sim JR. Intra-arterial air thrombogenesis after cerebral air embolism complicating lower extremity sclerotherapy. *Neurocrit Care.* 2009;11(2): 247-250.

advancing the art & science of medicine in the midwest

**WMJ**

*WMJ* (ISSN 1098-1861) is published through a collaboration between The Medical College of Wisconsin and The University of Wisconsin School of Medicine and Public Health. The mission of *WMJ* is to provide an opportunity to publish original research, case reports, review articles, and essays about current medical and public health issues.

© 2018 Board of Regents of the University of Wisconsin System and The Medical College of Wisconsin, Inc.

**Visit [www.wmjonline.org](http://www.wmjonline.org) to learn more.**